



Bone tuberculosis with multiple locations : Case report

SOUFIANE SASSI, JAMAL OUJABER, RACHID BENCHANNA, HICHAM JANAHA, AMINE HARZIMI BENJELLOUN
Service de pneumologie hôpital militaire Avicenne, Marrakech

Introduction :

Tuberculosis is a major public health problem. Bone location is rare and accounts for 1 to 5% of all cases and 10 to 20% of extra-pulmonary forms. Due to long insidious and nonspecific symptomatology the diagnosis of the disease may be revealed late, with a major risk of sequelae and functional resonance. On the other hand, the condition is difficult to diagnose, since it is a pauci-bacillary form, and the pathogen is only exceptionally isolated. We report a new observation of multiple-localized bone tuberculosis involving both left coxitis, right sacroiliitis and pulmonary tuberculoma.

Clinical observation :

This is a 28-year-old patient, married and the mother of a low socio-economic child with a recent notion of TB. For the past seven months, the patient had been accusing paroxysmal lumbagos, sometimes responding to NSAIDs, and sometimes relapses. Evolution was marked by worsening of algal symptomatology with partial functional impotence, lameness and close painful episodes associated with morning diversion, and not relieved by usual painkillers, all evolving in a context of anorexia, vesperal fever and AEG with loss of 10 kg in 5 months. In addition, the patient had left chest basal pain associated with a productive cough bringing back greenish sputum, which motivated her consultation with the pneumology department. The clinical examination found a patient in fairly good general apyretic condition, stable on the hemodynamic and respiratory level, with a BMI at 17 kg/m². The pleuro-pulmonary examination showed a left basal condensation syndrome. Osteo-articular examination showed on the one hand a stiffness of the sacroiliac joint with reduction of the distance of the ground finger and on the other hand a painful limitation of passive abduction of the left hip. The rest of the clinical examination was uncharted. X-ray of the thorax showed a limited and oval-circumscribed left basal opacity (Figure 1). Direct examination of BK sputum research was positive. CRP was 33 mg/l and HIV serology was negative. In addition, x-rays of the pelvis showed a pinch of the left coxo-femoral interline with irregular joint banks (Figure 2).

In view of this symptomatology, it was decided to perform a guided scan of the lung mass, the anatomopathological result of which showed an epithelioid granuloma and cellular giant with a caseous necrosis diagnosing a tuberculoma (Figure 3).

A diagnosis of pulmonary and bone localization tuberculosis was then diagnosed and antibacillary therapy was started using the 2RHZE/7RH protocol.

The evolution at nine months of treatment was characterized by the regression of active lesions including the collections of soft parts, weight gain, with a vicious left call in the form of coxarthrosis.

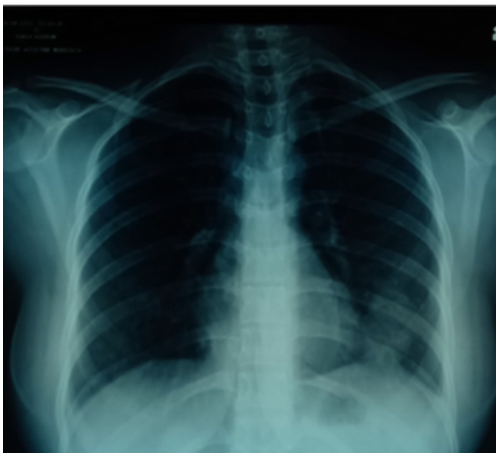

Figure 1: Chest x-ray showing left basal tuberculoma

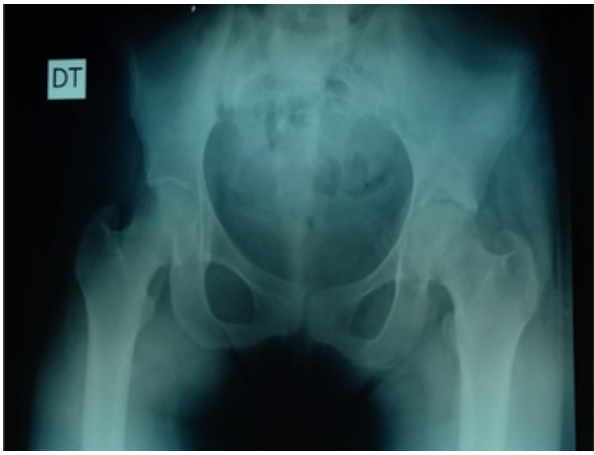

Figure 2: Front pelvis x-ray showing pinching of the left coxo femoral line space.

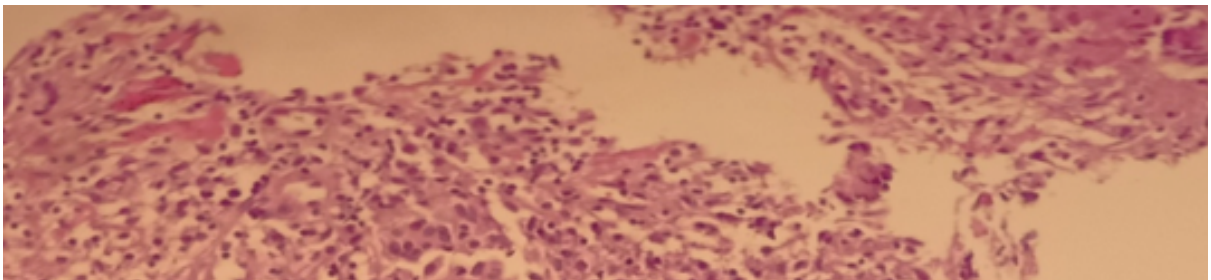


Figure 3: Gigantocellular granulomatous reaction with caseous necrosis (hematoxylin-eosin staining). Magnification 20. (our case).

Discussion :

The main location of osteo-articular tuberculosis is vertebral and accounts for more than half of cases. Monofocal impairment is the usual form, while multiple location remains estimated between 3 and 20% of cases. Tuberculosis arthritis predominates in the lower limbs, estimated to affect the disease between 60 and 80% of cases. The disease results from the spread of mycobacterium Tuberculosis. This is most often a reactivation of an ancient location due to certain factors such as local trauma, or sometimes from a primitive mainly pulmonary outbreak as illustrated by our case. Risk factors are mainly immunodepression states such as diabetes, alcoholism, chronic corticosteroid use and mainly HIV infection. The concept of TB was described in the literature and was the case of our patient. Clinically, TB arthritis develops as chronic arthritis, which gradually worsens over several months. The time between the onset of the first symptoms and the diagnosis varies on average from 08 to 21 months. Cold abscesses are a common complication of the disease with often a fistulized trait. In coxalgia, they can sit at the Scarpa triangle, in the adductor's lodge, in the gluteal region and in the pelvis. Due to the significant delay between the onset of symptoms and diagnosis, the condition is often discovered at a late stage with pinching of joint interline, geodes or bone erosions (Radiological Stage III), as our observation illustrates, see almost complete destruction with joint deformation (radiological stage VI). CT scans appear to be more sensitive to bone lesion analysis, while MRI is of great interest, further showing synovial pannus, joint effusion, and periarticular abscess. The positive diagnosis can be retained according to elements of presumption, by bringing together a common argument, clinical, epidemiological, the positivity of the tests of quantification of the interferon Gamma IGRAS whose specificity is better compared to the tuberculin skin test which is less and less used because of the frequency of false positives. The diagnosis can be retained by highlighting TH in other locations including pulmonary, as has been shown in our case. The bedrock of the diagnosis remains bacteriological, isolating the pathogen primarily at the lesion level, most often by scanned per cutaneous biopsy, or surgically by arthroscopy. It is necessary to recommend a double sample, the first to be intended to bacteriological and a second for histological signature in search of the epithelioid cellular granuloma giant. The advent of molecular biology techniques, especially the Xpert MTB. Rif has enabled a more sensitive and faster diagnosis in addition to the search for resistance to rifampicin, by detecting the mutation of the rpoB gene. Moreover, the pauci bacillary nature of the condition limits the importance of this technique in the certain diagnosis. Tuberculosis was said to do not like the bister, which rarely heals, often worsens and always mutilates. Functional surgery such as arthrodesis or joint prosthesis is discussed when the after-effects are installed. While treatment is still medical based on the association of antibiotics according to the 2RHZE/4RH protocol of up to twelve months in some protocols.

Conclusion :

Osteo-joint tuberculosis is a difficult diagnosis that can be confused with other rheumatic conditions, which are responsible for a delay in diagnosis and most often resulting in dreadful functional consequences. Early diagnosis and well-conducted medical treatment to prevent failures and relapses are key to good management of the disease. The evidence of BK is necessary for a certain diagnosis, and the advent of molecular biology techniques seems promising in terms of bacteriological diagnosis.

Références :

1. Evanchick CC., et al. "Tuberculosis of peripheral joints: an often missed diagnosis". The Journal of Rheumatology 13 (1986): 187-189.
2. Houshian S., et al. "Bone and joint tuberculosis in Denmark. Increase due to immigration". Acta Orthopaedica Scandinavica 71.3 (2000): 312-315.
3. Babhulkar S and Pande S. "Extraspinal tuberculosis: unusual manifestation of osteoarticular tuberculosis". Clinical Orthopaedics and Related Research 398 (2002) :114-120.
4. Benbouazza K., et al. "Les aspects diagnostiques de la tuberculose ostéoarticulaire. Analyse d'une série de 120 cas identifiés dans un service de rhumatologie". Sem Hop Paris 75 (1999): 1057-1064.